

*Scholarly Activity from
your Clinical Practice*



Selim R. Benbadis, MD, FAAN, FACNS, FAES
University of South Florida
Morsani College of Medicine

Rohit Das, MD
University of Texas Southwestern
Medical Center at Dallas

WHY PUBLISH?

- Contribution to the field
- Reputation and visibility
- Satisfaction and ego 😊
- Marketing and referrals

“Every case is interesting”

- There is something to learn from most patients
- Single case? I am not a fan ...
 - Anecdote: the plural of anecdote is not “data”
 - Possibly a significant contribution but only if it has an *exceptional* teaching value, i.e something really unexpected

Visuals are great

- Most journals have a neuro-image or equivalent
- Minimal text (50-100 words, 2-4 references)
- Very easy with modern digital imaging, smartphones etc.
 - Imaging (MRI, CT, angio etc.)
 - EEG
 - EMG
 - Photographs
 - Videos: epilepsy and movement disorders journals

Small series of newly recognized entities

- Obvious: COVID
- Newly recognized syndrome PRES
- EEG examples:
 - BIRDS and the “Interictal-Continuum”
 - 2HELPS2B



Contents lists available at ScienceDirect

Epilepsy & Behavior Reports

journal homepage: www.elsevier.com/locate/ebcr



European
Neurology

Neurologic Image

Eur Neurol
DOI: 10.1159/000503627

Received: August 20, 2019
Accepted: September 16, 2019
Published online: October 31, 2019

European
Neurology

Neurologic Image

Eur Neurol
DOI: 10.1159/000506197

Case Report

Hypnopompic hypersynchrony: A hyper-read hypno-pattern

Neena Viswanathan*, Sukriye Damla Kara, Kathleen Murray, Selim R. Benbadis

Department of Neurology, University of South Florida, USA



Phasing Out the Fallacy of Phase Reversals

Kristen Zemina Amanda Pennington Selim Benbadis

Department of Neurology, University of South Florida, Tampa, FL, USA

Two Epilepsy Types (Not Seizure Types) in the Same Patient: A Rare but Interesting Occurrence

Ushtar Amin Selim R. Benbadis

University of South Florida, Tampa, FL, USA



RESIDENT
& FELLOW
SECTION

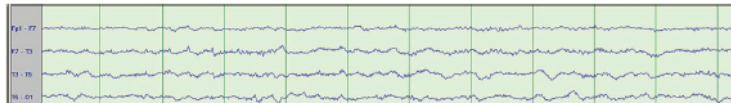
Section Editor
Mitchell S.V. Elkind,
MD, MS

Mystery Case: Sawtooth waves

Another normal variant not to over-read as epileptiform discharges

Yazan M. Suradi, MD
Fahad Salih Algreeshah,
MD
Noemi Rincon-Flores,
MD
Selim R. Benbadis, MD

Figure 1 Bipolar longitudinal (double-banana) montage



Neurology/Medicine

EEG Findings in Posterior Reversible Encephalopathy Syndrome

Kathleen Murray¹, Ushtar Amin¹, Stephanie Maciver¹,
and Selim R Benbadis¹

Clinical EEG and Neuroscience
2019, Vol. 50(5) 366–369
© EEG and Clinical Neuroscience
Society (ECNS) 2019
Article reuse guidelines:
sagepub.com/journals-permissions
DOI: 10.1177/1550059419856968
journals.sagepub.com/home/eeeg



RESIDENT & FELLOW SECTION

Teaching NeuroImages: Sleep-onset REM period during routine EEG

Karl A. Kasischke, MD, Amanda Pennington, MD, PhD, and Selim R. Benbadis, MD

Neurology® 2019;93:e1123-e1124. doi:10.1212/WNL.0000000000008108

Correspondence

Dr. Kasischke

kkasischke@health.usf.edu

EXPERT REVIEW OF NEUROTHERAPEUTICS

2020, VOL. 20, NO. 1, 3–5

<https://doi.org/10.1080/14737175.2020.1696193>

EDITORIAL


Reversing the myth of phase reversals

Sukriye Damla Kara^a, Ushtar Amin^a and Selim R. Benbadis^b

^aDepartment of Neurology, University of South Florida, Tampa, FL, USA; ^bEpilepsy and EEG,
Tampa, FL, USA

ARTICLE HISTORY Received 4 September 2019; Accepted 19 November 2019

KEYWORDS Artifact; EEG; epilepsy; epileptiform; misdiagnosis; phase reversals; normal variant



AUPN's Leadership Minute is brought
to you by...

***The Association of University
Professors of Neurology***

Copyright 2021